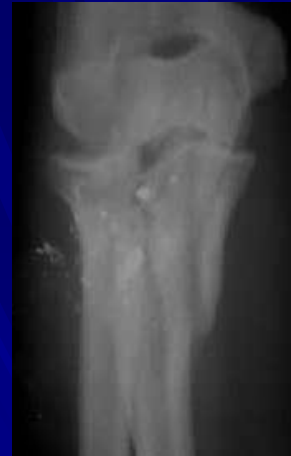
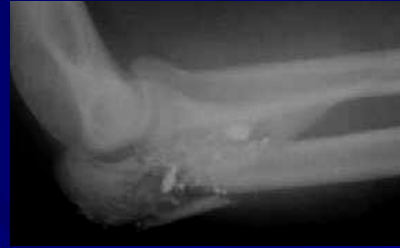
# Olecranonail®

## Case Presentation

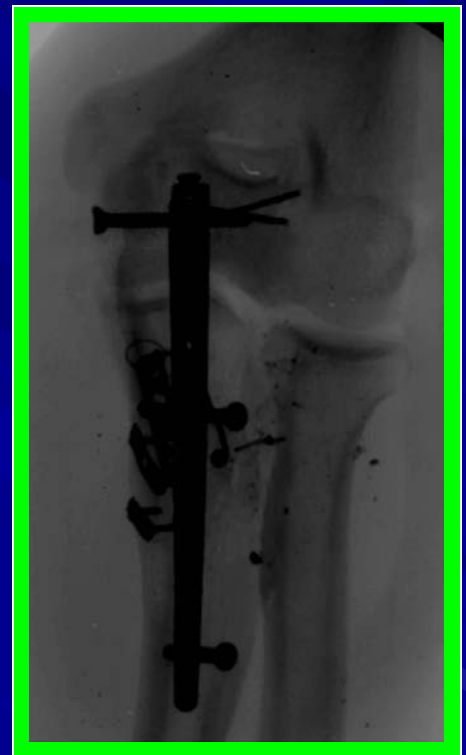
W. Andrew Eglseder, M.D.  
Assoc. Professor, Orthopaedic Surgery  
R Adams Cowley Shock Trauma Center  
University of Maryland Medical Center  
Baltimore, Maryland



27 year old was shot at point blank range with a 9mm handgun, sustaining a comminuted proximal ulna fracture.

*"I liked its versatility. You have lots of screw options where you need them."*

- Andy Eglseder, M.D.



**Stronger • Faster • Better**

Phone: (877) 87-MYLAD  
[www.myladortho.com](http://www.myladortho.com)